




## Use of Thick Split Thickness Sheet Skin Graft and its Outcome: A Case of Giant Congenital Melanocytic Nevus on the Face

Islam MM<sup>1</sup>, Rahman MA<sup>2</sup>

<sup>1</sup>Dr. Md. Maruful Islam, MS (Plastic Surgery), FACS, Associate Professor & Head, Department of Burn & Plastic Surgery, Khulna Medical College & Hospital

<sup>2</sup>Dr. Md. Ashfaqur Rahamn, MS (Orthopedics) Assistant Professor, Department of Orthopedics & Traumatology, Rangpur Medical College & Hospital, Rangpur

Case Report	Abstract:	DOI:
<p><b>Correspondence to:</b>  <b>Dr. Md. Maruful Islam</b>   maruf12nov@gmail.com</p>  <p>This open-access article is distributed under the terms of the Creative Commons Attribution 4.0 International License (CC BY 4.0), which permits unrestricted use, distribution, and reproduction in any medium, provided the original author and source are properly credited.</p>  <p>Scan the QR code for the Journal Homepage</p>	<p><b>Introduction:</b> Cutaneous melanocytic nevi cause cosmetic defects and represent a risk of malignant transformation. Facial Giant Congenital Melanocytic Nevus (GCMN) represents a major cosmetic deformity for the patient and is a challenge for plastic surgeons to achieve the best cosmetic results. Here in, a case of single-stage surgical reconstruction was presented using a partial thickness sheet skin graft for a facial GCMN. <b>Methods:</b> A 14-year young girl presented with left-sided hemifacial GCMN with the nose, left ala, lower eyelid, and partial upper eyelid-eyebrow involvement. A single-stage complete excision of the nevus was performed. A thick split-thickness skin was then harvested from the medial site of the thigh for the reconstruction of the defect. Aesthetic subunit of the face and nose keeping in mind the graft applied in this manner. The graft was secured with a bolster tie over the dressing and for the eyelid, the applied quilting technique was additionally for the aim of the best outcome with no skin loss. <b>Results:</b> Histopathology of the excised specimen confirmed the diagnosis of GCMN with no evidence of melanoma. The donor area healed with a favorable scar. The postoperative result was satisfactory. In long-term follow-up, the patient was able to close her eyes smoothly, ala seems better. The patient and her parents are very satisfied with the cosmetic and functional results. <b>Conclusion:</b> Thick split-thickness sheet skin grafts is an effective method of repairing the defects resulting from the removal of large and giant nevus of the face, where there is limited availability of normal adjacent skin for tissue expansion.</p> <p><b>Keywords:</b> Giant congenital melanocytic nevus (GCMN), Split thickness Sheet skin graft, Malignancy.</p>	

|| BSAPS Journal || Publication History - Received: 15.05.2021 || Accepted: 15.06.2021 || Published: 25.07.2021 ||

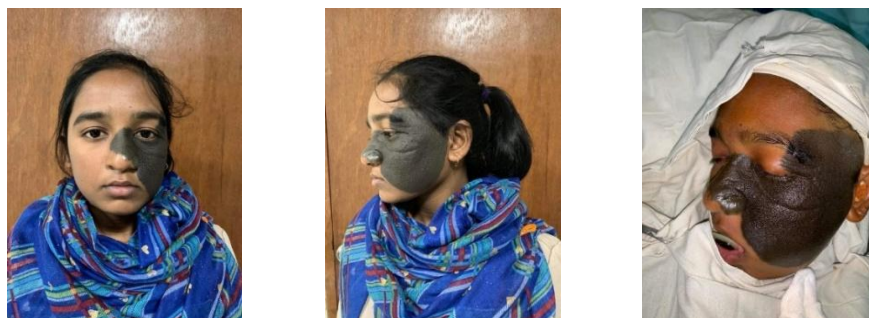## INTRODUCTION

Giant congenital melanocytic nevus (GCMN) is commonly defined as a melanocytic lesion present at birth involving more than 2% body surface area in infants and toddlers, that reaches a diameter of >20cm in adulthood.<sup>1-3</sup>

Two points should be noted for the treatment of GCMN. First, these lesions are associated with a risk of malignant melanoma, with a reported incidence of melanoma in patients with GCMN of 0.7% -8.2%.<sup>1,4</sup> A larger nevus has an increased risk of malignant transformation. Second, the cosmetic appearance of black hairy lesions can cause psychological effects. Based on these considerations, various methods including surgical excision, curettage, and dermabrasion have been reported.<sup>1</sup> Among these, early prophylactic surgical excision is recommended to reduce the risk of malignant transformation of skin lesions.<sup>5</sup> As nevus cells are histologically present in the entire dermal layer, complete removal of GCMN results in a full-thickness skin defect, which is usually difficult to reconstruct in the child. A lesion on the face represents a major cosmetic deformity for the child and is a challenge for plastic surgeons to achieve the best cosmetic results. In total, 70% of melanomas are diagnosed by the age of 10 years.<sup>6,7</sup> The relative risk of developing melanoma within a GCMN varies among types from 5% to 10% over one's lifetime.<sup>8</sup> Hence early prophylactic excision and reconstruction are advisable.<sup>9,10</sup> The goal of treatment is complete excision with satisfactory cosmetic reconstruction. Therefore, during treatment decisions, factors such as psychological effects and the risk of surgery and malignant transformation should be considered.<sup>11</sup> We report here a case of a girl who underwent single-stage lesion resection and aesthetic subunit reconstruction with a thick split-thickness sheet skin graft, with acceptable functional and aesthetic results.

## CASE REPORT

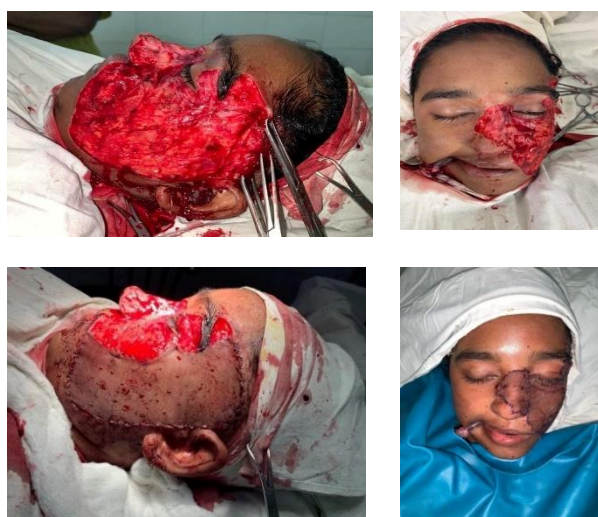In January 2019, a 14 years young girl presented with an extensive, large, black, non-hairy skin patch over the left cheek, lower eyelid, partial part of upper eyelid-eyebrow, and nose since birth. This nevus had been increasing in size at the same rate as the facial growth. There was no family history of similar lesions or skin cancer. The patient had no neurological symptoms and was not taking any medications or ever taking any type of treatment for that problem. Examination revealed a large pigmented patch measuring approximately 14 cm in its greatest diameter on the left periorbital area and extended to cover nearly half of the face (Fig- 1). There was no color change or increase in size. No other specific complaints like pain, itching or discharge. No other satellite lesions were present over the body. We performed a single-stage complete excision of the lesion under general anesthesia. The surgical risks and benefits, and the potential for malignancy were discussed with the patient and her family.



**Figure 1. The pre-operative view of the giant congenital melanocytic nevus. Extensive black lesion on the left side of the face. Note the involvement of the lower eyelid and ala of the nose of the affected side**

The thick split-thickness skin graft was harvested from the medial side of the thigh. Subsequently, the resulting defect was covered with the thick split-thickness sheet skin graft by securing the edge of the defect with a 5/0 non-absorbable proline suture (Fig-2).

A separate sheet of skin was applied to different anatomic areas following the subunit principle of reconstruction where feasible. A few mini pores were made in the skin sheet for squeezing any collection beneath the graft. In the process, meticulous hemostasis was acquired by selective electrocoagulation in the excised area. The operative site was dressed in wet sofra tulle with 2% mupirocin ointment and then 10% povidone-iodine-soaked wet cotton. Finally, the grafts were secured with bolster tie-over dressing to ensure immobilization. The patient received prophylactic antibiotics (Inj. Moxifloxacin) post-operatively.



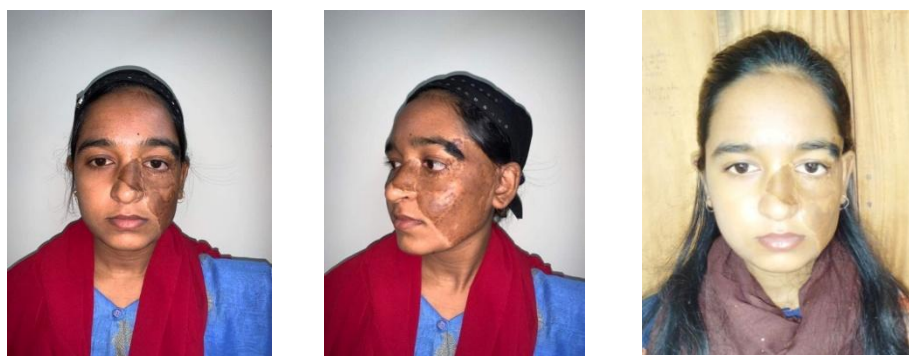**Figure 2. Per operative view of the facial lesion after excision, followed by the application of thick split-thickness sheet skin graft. Note that the tiny pore rather meshes to the skin and applied quilting suture at lower eyelid area**

The dressing was changed after 5 days, which showed a tiny graft loss. Preoperative and post-operative digital photographs were taken to evaluate long-term outcomes through follow-up. The postoperative result was satisfactory with good color, color match, and thickness to cover the giant defect created after excision. Coconut butter lotion and emollient were advised to apply to the graft area postoperatively, for a long. Long-term follow-up visits revealed that the patient and her family

were very satisfied with the cosmetic and functional results. The final follow-up photo was taken after 2 years of operation (Fig-3).

## DISCUSSION

The choice of method of plastic surgery is specific for each patient and depends on the size and location of the defect. If the treatment strategy is improperly selected, severe scarring may form, resulting in ectropion, lip eversion, nasal atresia, and other deformities. A recent study demonstrated that early excision of the giant lesions reduces the risk of malignant melanoma and the associated psychological distress in the child and parents<sup>3,12</sup>. Several therapeutic procedures have been considered. Non-surgical options include dermabrasion, laser ablation, curettage, and chemical peeling. Since it is impossible to eliminate the risk of malignant transformation, GCMN removal is a reconstructive and aesthetic procedure rather than prophylactic surgery<sup>13-15</sup>. Recent advances have led to a multitude of surgical approaches for the treatment of large and GCMN including tissue expansion, serial excision, and either full thickness or a split-thickness skin graft. However, none of the currently available surgical methods is universally accepted. Tissue expansion is a useful method for providing additional tissue to resurface the giant defect created after the removal of nevus and acquires functional and aesthetic outcomes. However, the complications and limitations of tissue expansion are commonly described and are often reported to be greater in children<sup>16,17</sup>. The major complication of the expansion includes infection, expander exposure, and implant failure<sup>18</sup>. Moreover, the tissue expansion applied in patients with large GCMN requires multiple stages. Serial excision is a preferred treatment method for congenital melanocytic nevus that can be excised in not more than two procedures<sup>19</sup>. But it is not recommended for large lesions involving the face, ear, and neck as it avoids the distortion of involved or adjacent structures and function loss. In the above anatomic site, skin grafting is recommended. Full-thickness skin grafts versus split-thickness skin grafts are preferred for the reconstruction of the face, ear, neck, and hand. The full-thickness skin graft was applied to the defect after the excision of the nevus and the grafted skin had excellent contour, color match, texture, and thickness<sup>20,21</sup>. But unfortunately, this huge amount of full-thickness skin harvesting is very difficult and challenging; the donor site is a great concern. In this case, a thick split-thickness skin graft was used, keeping it in sheet form without any mesh, and made some pores only to aim for a collection-free recipient field. The graft was then applied to the facial skin defect site, with full attention to the anatomical features of the face. Though the aesthetic outcome of a split-thickness skin graft is not very satisfactory for facial reconstruction, a thick sheet graft may be applicable and recommended for the large defect on the face. In long-term follow-up, a satisfactory functional and aesthetic outcome was found in this case study.



**Figure 3. The result after a follow-up period of 2 years. The grafted skin has taken without any loss and contracture; color matching is acceptable with no sign of ectropion**

## CONCLUSION

Thick split thickness sheet grafting is a safe and effective method to repair the huge defects of the excised facial GCMN and get a satisfactory cosmetic outcome with maintaining proper function and reducing the risk of degeneration. Slight facial makeup is sufficient for camouflaging the defect and thus increasing the confidence level of the sufferer.

## REFERENCES

1. Arad E, Zuker RM. The shifting paradigm in the management of giant congenital melanocytic nevi: Review and clinical applications. *Plast Reconstr Surg*. 2014;133:367-376.
2. Bittencourt FV, Marghoob AA, Kopf AW, Koenig KL, Bart RS. Large congenital melanocytic nevi and the risk for development of malignant melanoma and neurocutaneous melanocytosis. *Pediatrics* 2000; 106: 736-741
3. Corcoran J, Bauer BS. Management of large melanocytic nevi in the extremities. *J Craniofac Surg*. 2005; 16: 877-885.
4. Watt AJ, Kotsis SV, Chung KC. Risk of melanoma arising in large congenital melanocytic nevi; a systemic review. *Plast Reconstr Surg*. 2004;113:1968-1974.
5. Marghoob AA, Agero AL, Benvenuto-Andrade C, et al. Large congenital melanocytic nevi, risk of cutaneous melanoma, and prophylactic surgery. *J Am Acad Dermatol*. 2006; 54:868-70; discussion 871.

6. Reed WB, Becker SW Sr, Becker SW Jr, Nickel WR. "Giant pigmented" nevi, melanomas and leptomeningeal melanocytosis. *Arch Dermatol*. 1965;91: 101-19.
7. Dedavid M, Orlow SJ, Provost N, et al. A study of large congenital melanocytic nevi and associated malignant melanomas: review of cases in the New York University registry and the world literature. *J Am Acad Dermatol*. 1997; 36:409-16.
8. Viana AC, Gontijo B, Bittencourt FV. Giant congenital melanocytic nevus. *An Bras Dermatol*. 2013;88:863-78.
9. Arneja JS, Gosain AK. Giant congenital melanocytic nevi of the trunk and an algorithm for treatment. *J Craniofac surg*. 2005;16:886-93.
10. Gosain AK, santoro TD, Larson DL, Gingrass RP. Giant congenital nevi: a 20-year experience and an algorithm for their management. *Plast Reconstr Surg*. 2001; 108:622-36.
11. Marghoob AA. Congenital melanocytic nevi: evaluation and management. *Dermatol Clin*. 2002;20(4):607-16.
12. Weinberg MJ, Al-Qattan M, Zuker RM, Thomson SG, Lindsay WK. Congenital giant pigmented nevi: clinical features and risk of malignancy. *Can J Plast Surg*. 1996;4:94-8.
13. Zuckerman R, Maier JP, Guiney WB Jr, Huntsman WT, Mooney EK. Pediatric melanoma: confirming the diagnosis with sentinel node biopsy. *Ann Plast Surg*. 2001;46:394-9.
14. Ionomou T, Michelo BJ, Zuker RM. Tissue expansion in the pediatric patient. *Ann Plast Surg*. 1993;31:134-40.
15. Foster RD, Williams ML, Barkovich AJ, Hoffman WY, Mathes SJ, Frieden IJ. Giant congenital melanocytic nevi: the significance of neurocutaneous melanosis in neurologically asymptomatic children. *Plast Reconstr Surg*. 2001;107:933-41.
16. Dotan L, Icekson M, Yanko-arzi R, Ofek A, Neuman R, Margulis A. Pediatric tissue expansion: our experience with 103 expanded flap reconstructive procedures in 41 children. *Isr Med Assoc J*. 2009;11:474-9.
17. Steenfoss H, Tarnow P, Blomqvist G. skin expansion. Long term follow up of complications and costs of care. *Scand J Plast Reconstr Surg Hand Surg*. 1993;27:137-41.
18. Manders EK, Schenden MJ, Furrey JA, Hetzler PT, Davis TS, Graham WP 3rd, Soft tissue expansion: concepts and complications. *Plast Reconstr Surg* 1984; 74:493-507.
19. Altchek ED. A technical consideration of the serial excision of a nevus. *Plast Reconstr Surg* 1980;66:849-850.
20. Rao K, tillo O, Dalal M, Full thickness skin graft cover for lower limb defects following excision of cutaneous lesions. *Dermatol Online J* 2008;14:4.
21. ganesyan G, Jarell AD, Srivastava M, Jiang SI. Efficacy and complication rates of full thickness skin graft repair of lower extremity wounds after Mohs micrographic surgery. *Dermatol Surg* 2013; 39: 1334-1339.